

Relationship between Retinal Vascular Changes with Blood Pressure and Heart Rate of Workers in a Tile and Ceramic Industries

Fatemeh Aminaei¹, Fatemeh Ghanaei², Seyed Jalil Mirmohammadi³, Amir Houshang Mehrparvar⁴,
Mohsen Gohari^{5*}, Hosein Falahzadeh⁶, Mohammad Javad Zare Sakhvidi⁷

¹ Department of Occupational Health, Shahid Sadoughi University of Medical Sciences, Yazd, Iran • ² Department of Occupational Health, Shahid Sadoughi University of Medical Sciences, Yazd, Iran • ³ Department of Occupational Medicine and Industrial Diseases Research Center, Assistant Professor, Shahid Sadoughi University of Medical Sciences, Yazd, Iran • ⁴ Department of Occupational Medicine and Industrial Diseases Research Center, Professor, Shahid Sadoughi University of Medical Sciences, Yazd, Iran • ⁵ Department of Ophthalmology, Assistant Professor, Geriatric Ophthalmology Research Center, Shahid Sadoughi University of Medical Sciences, Yazd, Iran • ⁶ Department of Biostatistics and Epidemiology, Shahid Sadoughi University of Medical Sciences, Yazd, Iran • ⁷ Department of Occupational Health, Faculty of Health, Shahid Sadoughi University of Medical Sciences, Yazd, Iran • Corresponding Author: Mohsen Gohari, Email: goharimo@yahoo.com, Tel: +98-913-3535012

Abstract

Background: Various studies have shown that vascular changes in the retina can be a primary indicator of cardiovascular disease risk. CRAE, CRVE, and AVR are three important markers for determining retinal vascular changes. The aim of this study was to determine the changes in these three ocular markers and their relationship with blood pressure and heart rate.

Method: In this cross-sectional analytical study, 96 workers from one of Yazd's tile and ceramic industries were studied. Fundus images were prepared from both eyes and then analyzed using ARIA software and related protocols. Data were analyzed by Kolmogorov-Smirnov test, and Mann-Whitney test and Correlation test was performed. **Results:** The mean and standard deviation of age and working experience of the population under study were 34.93(6.06) and 9.85(6.26) years, respectively. There was no statistically significant correlation between ocular parameters with blood pressure and heart rate (p-value >0.05). The relationship of CRAE and CRVE with heart rate, although not statistically significant, was inverse.

Conclusion: The results of this study showed no relationship between retinal vascular changes with changes in cardiovascular parameters such as blood pressure and heart rate among workers. Also, there was no significant difference between BMI and mean of three ocular parameters.

Keywords: Retinal vascular; Blood pressure; Heart rate; Tile industry

Introduction

Ischemic heart disease and stroke are the most common causes of death in the United States.¹ Approximately 12 million people in the United States are suffering from heart disease, and this is the leading cause of death in adults in the United States and 22% of deaths in the world. In Iran, the first and most common cause of death in all ages and both

males and females is cardiovascular disease, so much that out of 700 to 800 deaths per day, 317 cases are due to cardiovascular disease, 166 of which are due to the heart attack after the age 35.² In addition to blood circulation in large vessels, microcirculation also plays an important role in the physiology and health of the cardiovascular system. Microcirculation

Citation: Aminaei F, Ghanaei F, Mirmohammadi SJ, Mehrparvar AH, Gohari M, Falahzadeh H, et al. Relationship between Retinal Vascular Changes with Blood Pressure and Heart Rate of Workers in a Tile and Ceramic Industries. Archives of Occupational Health. 2018; 2(2): 89-95.

Article History: Received: 28 November 2017; Revised: 14 January 2018; Accepted: 1 March 2018

Copyright: ©2017 The Author(s); Published by Shahid Sadoughi University of Medical Sciences. This is an open-access article distributed under the terms of the Creative Commons Attribution License (<https://creativecommons.org/licenses/by/4.0/>), which permits unrestricted use, distribution, and reproduction in any medium, provided the original work is properly cited.

is the blood circulation between in the smallest blood vessels of the human body.³ Microcirculation consists of blood vessels with a diameter of less than 150 micrometers, which constitute the major part of the cardiovascular system, and delivery of nutrients, removal of metabolites and exchange of gases (O₂ and CO₂) with organs of the body are among their duties. For this reason, any dysfunction in the cross-section of these vessels, as well as the presence of inflammatory factors, will have a more severe effect on their proper functioning.^{4,5} Changes in the autonomy function of heart, functional changes in micro and macrovascular systems, induction of systemic inflammation, endothelial dysfunction, changes in peripheral resistance of blood vessels, and eventually changes in microcirculation can lead to cardiovascular complications.⁶ Capillary changes can be a primary indication of the onset of cardiovascular disease or an indication of the course of these diseases.⁷ Microcirculation plays an important role in regulating blood pressure, and diseases associated with small vessels are one of the pathological causes of high blood pressure.⁵⁻⁸ However, the relationship between the changes in the microcirculation of small veins (venules and arterioles), which form a large part of the circulatory system, is not clear with the development of chronic diseases, especially cardiovascular disease.⁹ Studying and direct observing of microcirculation changes is difficult.^{10,11} Studying the involvement of small retina vessels by retinal imaging is a noninvasive invivo method that allows for the examination of changes in the small retinal capillaries (with a diameter of 60-300 μm).^{1,12,13} In other words, many of the major diseases, such as diabetes, diabetic retinopathy and various strokes, are first revealed in the retina and they originate in the eye, brain, or cardiovascular system, which can be detected by imaging the eyes and the study of analysis of these images.¹⁴ Symptoms such as narrowing of the retinal arteries,

abnormal increase of the intracranial cysts, retinal spots, spotting or swelling of the optical disc independent of other influential factors can be evidence of hypertension.¹⁵ High blood pressure, aging, diabetes and cardiovascular disease cause problems such as arterial stenosis, arterial gap, retinopathy and ... in small retina vessels.¹⁶ Because workers are at risk for cardiovascular diseases, such as blood pressure, in the present study, retinal vascular changes were evaluated using fundus photographic method.

Methods

This research is descriptive analytical and cross-sectional which was conducted in the year 2016 in one of the tiles and ceramic industries of Yazd. The study protocol was in accordance with institutional medical ethics board and approved by the ethic committee of the University (IR.SSU.SPH.REC.1395.107). The statistical population in this research included all workers working in different units of the related industry. The method of the present study was in four stages as follows. 1- Screening the sample subjects 2- Fundus photography 3- Analyzing images 4- Measurement of cardiovascular parameters.

Sample screening: After reviewing the medical records of workers, people without a history of cardiovascular disease, ocular diseases, diabetic retinopathy, and any disorder affecting the study were screened. The criteria for entering the study were a work experience of at least one year in the industry. Due to the different parameters in the study, female workers were excluded from the study. Eventually, 96 healthy male workers were selected for research purposes. After obtaining a written informed consent from the subjects, their demographic characteristics were collected using a pre-made questionnaire from the researcher.

Fundus Photography: At first, the researcher was trained to take Fundus photography. Subjects

were then placed in a dark place designated for fundus photography. Because of the sensitivity of the fundus imaging to light, the presence of people in this place was necessary. The digital camera Canon CR-2 AF non-mydratic 20.2-megapixel with a 45° angle was used for retina imaging. Fundus images were taken from subjects' both eyes for 5 minutes and re-imaging was performed in the absence of high-quality images. During the fundus photography, subjects with a small pupil were provided with mydratic.¹⁷

Image Analysis: This step was carried out according to the proposed protocols with a few changes and the Automated Retinal Image Analyzer (ARIA) software was used. Using the related software according to Fig. 1, from the optical disk margin concentric circles were drawn at a distance of half or one time the diameter of the disk.¹⁸ The diameter of six arterioles and the six larger venules of this region were measured in micrometers.

After measuring the diameter of the vessels, three markers, central retinal arteriolar equivalents (CRAE), central retinal venular equivalent (CRVE) and arterial (Retinal Arterio-Venule-Ratio) (AVR) were calculated using the Parr-Hubbard equation.¹⁹

Para-Hubbard equation:²⁰

For the CRAE

$$W_{New} = (0.87 * W_{2small} + 1.01 * W_{2large} - 0.22 * W_{small} * W_{large} - 10.76) 0.5$$

For the CRVE

$$W_{New} = (0.72 * W_{2small} + 0.91 * W_{2large} + 450.05) 0.5$$

Cardiovascular Parameters: To determine the relationship between retinal vascular changes and cardiovascular parameters, systolic blood pressure, diastolic blood pressure, heart rate, and body mass index (BMI) of 96 subjects were measured. Before doing these measurements, the subjects did not have any physical activity for at least five minutes. During the break, their waist and wrist circumference was measured with a tape measure. Systolic blood pressure, diastolic blood pressure, and heart rate were measured five times consecutively, and the mean of three final measurements was taken.^{3,21} Systolic blood pressure (SBP) (Diastolic Blood Pressure) (DBP) was measured using the Emsig SP05 barometer and heart rate (HR) and also the Himmel HP-10 pulse oximeter.

Statistical analysis: Data were inserted into the spss software and then necessary statistical analyses were performed. The results were analyzed using descriptive statistics of SPSS21 software such as percentage, mean, standard deviation, and appropriate statistical tests such as Kolmogorov-Smirnov test, correlation, and Mann-Whitney test.

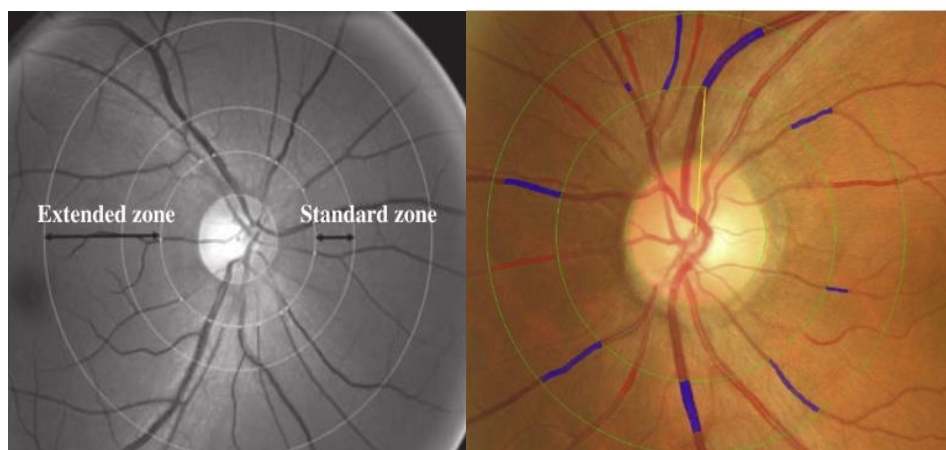


Figure 1. A retinal region with a diameter of one to half times the optical disk, venules in blue and arterioles in red.

Results

In this study, all subjects were male. The mean and standard deviation of age and their working experience were 34.93 (0.60) and 9.85 (4.62) respectively. To test the normal distribution of variables, the Kolmogorov-Smirnov test was used. The results of the test showed that the two variables CRAE and CRVE follow the normal distribution (CR-value of p-value = 0.20 and CRAE p-value = 0.10). But the AVR variable does not follow the normal distribution (P -Value = 0.040). The subjects were classified into three categories: normal, overweight, and obese.

To study the relationship between the mean and standard deviation of ocular parameters with BMI of subjects for normal data, T-student and ANOVA tests, and for abnormal data, Mann-Whitney and Kruskal-Wallis tests were used. The results were obtained according to table 1.

According to the results of the above table, there was no significant difference between BMI and mean of the three ocular parameters, and in other words, the mean in compared groups is not different. Pearson Correlation test obtained a correlation between CRAE, CRVE and AVR parameters with systolic blood pressure, diastolic

blood pressure, heart rate, waist circumference and wrist circumference for normal data and abnormal data by Spearman test according to Table 2.

According to the results of the above table, there was no statistically significant relationship between CRAE, CRVE and AVR parameters with systolic blood pressure, diastolic blood pressure, heart rate, wrist, and waist circumference (P -Value > 0.05). The relationship of CRAE and CRVE with heart rate, though not statistically significant, was inverse.

Pearson correlation coefficient and Spearman correlation coefficient were used to determine the relationship between ocular and age parameters. This coefficient for the CRAE, CRVE and AVR parameters was 0.02-0.03 and 0.10, respectively, which were not statistically significant. Finally, ANOVA and Kruskal-Wallis tests were used to examine the relationship between the mean of ocular parameters and workers' shift. According to the results, there was a statistically significant correlation between the mean CRVE and the work-shift (P -Value = 0.04). However, no statistically significant relationship was found between the mean of CRAE, AVR and work-shift (P -Value = 0.20, 0 = P -Value).

Table 1. The Relationship between Ocular Parameters and Body Mass Index.

	variable	frequency	CRAE mean(SD)	CRVE mean(SD)	AVR mean(SD)
Body mass index	normal	45	163.79(17.95)	225.80(23.09)	0.72(0.06)
	overweight	39	171.25(18.33)	229.53(22.79)	0.74(0.06)
	obese	12	163.43(15.21)	224.16(28.76)	0.73(0.07)
	P -Value	-	0.13	0.69	0.03

Table 2. Correlation between Ocular Parameters and Heart Parameters

	variables	Heart rate	Waist circumference	Wrist circumference	Systolic blood pressure	Diastolic blood pressure
CRAE	Correlation coefficient	-0.03	0.11	-0.01	-0.17	-0.13
	P -Value	0.74	0.30	0.91	0.01	0.18
CRVE	Correlation coefficient	-0.04	-0.01	-0.05	0.05	-0.17
	P -Value	0.69	0.92	0.60	0.65	0.09
AVR	Correlation coefficient	0.01	0.18	0.04	-0.15	0.01
	P -Value	0.96	0.01	0.60	0.15	0.90

Correlation is significant at the 0.01 level (2-tailed)."

Discussion

Blood pressure is a measure of the power with which blood circulates on the wall of the arteries. High blood pressure is one of the most important non-communicable diseases that has increased dramatically in developing societies during the last few decades. The severity of the complications depends on race, sex, increased blood fat, diabetes, and so on. One of the pathological causes of high blood pressure is small-vessel-related diseases. Specifically, the contraction and narrowing of the small peripheral vessels cause a rise in blood pressure. The most important side effect of high blood pressure is the increased risk of cardiovascular disease.^{5,8,22} In the retina, different symptoms, such as narrowing of the retinal arteries, an abnormal increase of the retinal staining, spotting, or swelling of the optical disc, independent of other influential factors, can be evidence of hypertension [15]. In this study, the three parameters of CRAE, CRVE, and AVR in ceramic –tile workers were investigated by standard imaging to investigate the relationship between blood pressure and heart rate and retinal vascular changes. The results of this study did not show a significant difference between the changes in ocular parameters with heart rate and blood pressure. The study of Wong and colleagues is in tandem with our study. With the difference that in his studies, the relationship between changes in the diameter of the small vessels of the retina, especially the narrowing of the arteries with cardiovascular disease, was observed only in women, and the researcher did not see such a relationship in men. He and his colleagues believe that factors such as smoking, diabetes, high blood pressure and elevated lipid plasma levels increase the risk of developing cardiovascular disease in women following changes in the diameter of small retinal vessels.²³ However, in this study, the statistical population of the study was male, and due to the different parameters of the study, women were excluded from our research. Findings of Ljungman et al. show that dilatatory responses of small vessels in

microcirculation has no significant relation with a heart attack and related disorders, and this response can only be used to regulate systolic blood pressure.²⁴ But some studies support results which are contradictory to our study. Cheung and colleagues believe that the thinner diameter of retinal vasculature can be a predictive factor of cardiovascular disease, hypertension, heart rate, and so on. From the viewpoint of this researcher, there is a statistically significant difference between changes in the diameter of the retina with hypertension, heart rate, and other cardiovascular disorders.²⁵

Given that blood pressure is a highly variable factor that is affected by various factors and can be the cause or result of vascular dysfunction, our study did not have enough power to fully understand the factors affecting it and to recognize its role. On the other hand, our study population was all young and healthy people who had no history of cardiovascular disease. Studies on changes in the diameter of the retina based around the fact that these changes, due to the combination of factors such as exposure to contaminated particles, can lead to increased heart rate, followed by hypertension. There is, of course, not enough evidence that this high blood pressure or heart rate can be the cause or result of changes in the retina.²⁶ Other reasons for the lack of significant relationship between blood pressure and heart rate with ocular parameters in the present study can be relatively low mean of the age in this study. Therefore, the effect of age can also be a possible explanation for our findings. Because young people with lower age are in very good health and the impact of adverse factors is less than that of the elderly. According to some studies, it can be predicted that with increasing age, the number of microvascular changes in the retina increases and age is an effective factor in increasing the risk of cardiovascular disease, hypertension, and heart rate.²⁷

In general, the results of this study showed that among workers without a history of cardiovascular disease in the ceramic and tile industry, changes in ocular parameters due to blood pressure and heart rate are very small and negligible. While the increase in these changes may indicate an increased risk of cardiovascular disease. In our study, we can not use these changes in the small sample size as a predictor of cardiovascular disease. In other words, this study supports the hypothesis that the accurate study of microvascular changes in the retina requires a large sample size. It is suggested that more samples should be used to ensure the accuracy and validity of this study and, in addition, the use of specialized software for measuring the diameter of the vessels with higher accuracy is recommended. For the reasons given, more research is needed to clarify the relationship between blood pressure and heart rate with ocular parameters.

Conflict of interest

The authors did not report any contradiction of interests.

Acknowledgments

At the end, we would like to thank the unconditional support of the respected president of Health Care Unit of Health Center No.2 of Isfahan province, Mrs. Motani, and the professors of Health Professionals Department at Shahid Sadoughi University of Medical Sciences in Yazd.

References

- Wong TY, Kamineni A, Klein R, Sharrett AR, Klein BE, Siscovick DS, et al. Quantitative retinal venular caliber and risk of cardiovascular disease in older persons: the cardiovascular health study. *Archives of internal medicine*. 2006;166(21):2388-94.
- Niakan M, Paryad E, Shekholeslam F, Kazemnezhad Leili E, Assadian Rad M, Bonakdar HR, et al. Self care behaviors in patients after myocardial infarction. *Journal of holistic nursing and midwifery*. 2013;23(2):63-70.[Persian]
- Louwies T, Panis LI, Kicinski M, De Boever P, Nawrot TS. Retinal microvascular responses to short-term changes in particulate air pollution in healthy adults. *Environmental health perspectives*. 2013;121(9):1011.
- De Boever P, Louwies T, Provost E, Panis LI, Nawrot TS. Fundus photography as a convenient tool to study microvascular responses to cardiovascular disease risk factors in epidemiological studies. *Journal of visualized experiments*. 2014(92).
- Louwies T. Turning an eye towards cardiovascular health: the retina in public health research. 2015.
- Louwies T, Nawrot T, Cox B, Dons E, Penders J, Provost E, et al. Blood pressure changes in association with black carbon exposure in a panel of healthy adults are independent of retinal microcirculation. *Environment international*. 2015;75:81-6.
- Wong TY, Klein R, Sharrett AR, Duncan BB, Couper DJ, Klein BEK, et al. Retinal arteriolar diameter and risk for hypertension. *Annals of internal medicine*. 2004;140(4):248-55.
- Wong TY, Shankar A, Klein R, Klein BEK, Hubbard LD. Prospective cohort study of retinal vessel diameters and risk of hypertension. *BMJ*. 2004;329(7457):79.
- Johnson PC. Overview of the microcirculation. Amsterdam: Elsevier; 2008. P: 6-20.
- Barrett JR. Particulate matter and cardiovascular disease: researchers turn an eye toward microvascular changes. *Environmental health perspectives*. 2013;121(9):282.
- Liew G, Wang JJ, Mitchell P, Wong TY. Retinal vascular imaging a new tool in microvascular disease research. *Circulation: cardiovascular imaging*. 2008;1(2):156-61.
- McGeechan K, Liew G, Macaskill P, Irwig L, Klein R, Klein BE, et al. Prediction of incident stroke events based on retinal vessel caliber: a systematic review and individual-participant meta-analysis. *American journal of epidemiology*. 2009;170(11):1323-32.
- Wong TY, Klein R, Couper DJ, Cooper LS, Shahar E, Hubbard LD, et al. Retinal microvascular abnormalities and incident stroke: the atherosclerosis risk in communities study. *The lancet*. 2001;358(9288):1134-40.
- Abramoff MD, Garvin MK, Sonka M. Retinal imaging and image analysis. *IEEE reviews in biomedical engineering*. 2010;3:169-208.
- Nguyen TT, Wong TY. Retinal vascular manifestations of metabolic disorders. *Trends in endocrinology & metabolism*. 2006;17(7):262-8.
- Wong TY, Klein R, Klein BEK, Tielsch JM, Hubbard L, Nieto FJ. Retinal microvascular abnormalities and their relationship with hypertension, cardiovascular disease, and mortality. *Survey of ophthalmology*. 2001;46(1):59-80.
- Adar SD, Klein R, Klein BEK, Szpiro AA, Cotch MF, Wong TY, et al. Air pollution and the microvasculature: a cross-sectional assessment of in vivo retinal images in the population-based multi-ethnic study of atherosclerosis. *PLoS medicine*. 2010;7(11).
- Wong TY, Knudtson MD, Klein R, Klein BEK, Meuer SM, Hubbard LD. Computer-assisted measurement of retinal vessel diameters in the beaver dam eye study: methodology, correlation between eyes, and effect of refractive errors. *Ophthalmology*. 2004;111(6):1183-90.
- Knudtson MD, Lee KE, Hubbard LD, Wong TY, Klein R, Klein BEK. Revised formulas for summarizing retinal vessel diameters. *Current eye research*. 2003;27(3):143-9.
- Schuster AKG, Fischer JE, Vossmerbaeumer U. Semi-automated retinal vessel analysis in nonmydiatic fundus photography. *Acta ophthalmologica*. 2014;92(1):42-9.
- Louwies T, Vuegen C, Panis LI, Cox B, Vrijens K, Nawrot TS, et al. Mima expression profiles and retinal blood vessel calibers are associated with short-term particulate matter air pollution exposure. *Environmental research*. 2016;147:24-31.
- Wong T, Mitchell P. The eye in hypertension. *The lancet*. 2007;369(9559):425-35.

23. Wong TY, Klein R, Sharrett AR, Duncan BB, Couper DJ, Tielsch JM, et al. Retinal arteriolar narrowing and risk of coronary heart disease in men and women: the Atherosclerosis Risk in communities study. *JAMA*. 2002;287(9):1153-9.
24. Ljungman PL, Wilker EH, Rice MB, Austin E, Schwartz J, Gold DR, et al. The impact of multipollutant clusters on the association between fine particulate air pollution and microvascular function. *Epidemiology*. 2016;27(2):194-201.
25. Cheung N, Islam FM, Jacobs DR, Sharrett AR, Klein R, Polak JF, et al. Arterial compliance and retinal vascular caliber in cerebrovascular disease. *Annals of neurology*. 2007;62(6):618-24.
26. Giorgini P, Rubenfire M, Bard RL, Jackson EA, Ferri C, Brook RD. Air pollution and exercise: a review of the cardiovascular implications for health care professionals. *Journal of cardiopulmonary rehabilitation and prevention*. 2016;36(2): 84-95.
27. Wong TY, Klein R, Nieto FJ, Klein BEK, Sharrett AR, Meuer SM, et al. Retinal microvascular abnormalities and 10-year cardiovascular mortality: a population-based case-control study. *Ophthalmology*. 2003;110(5):933-40.